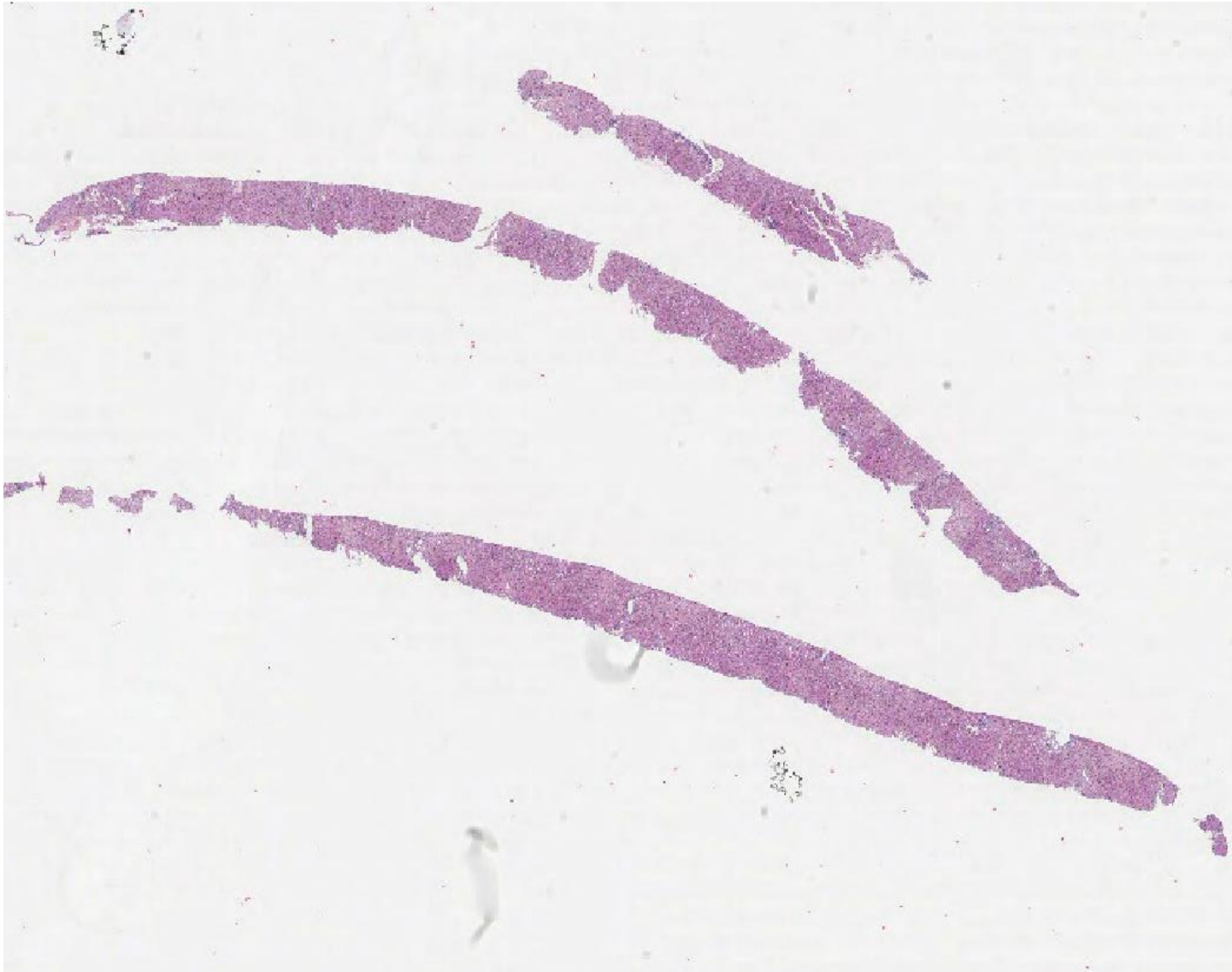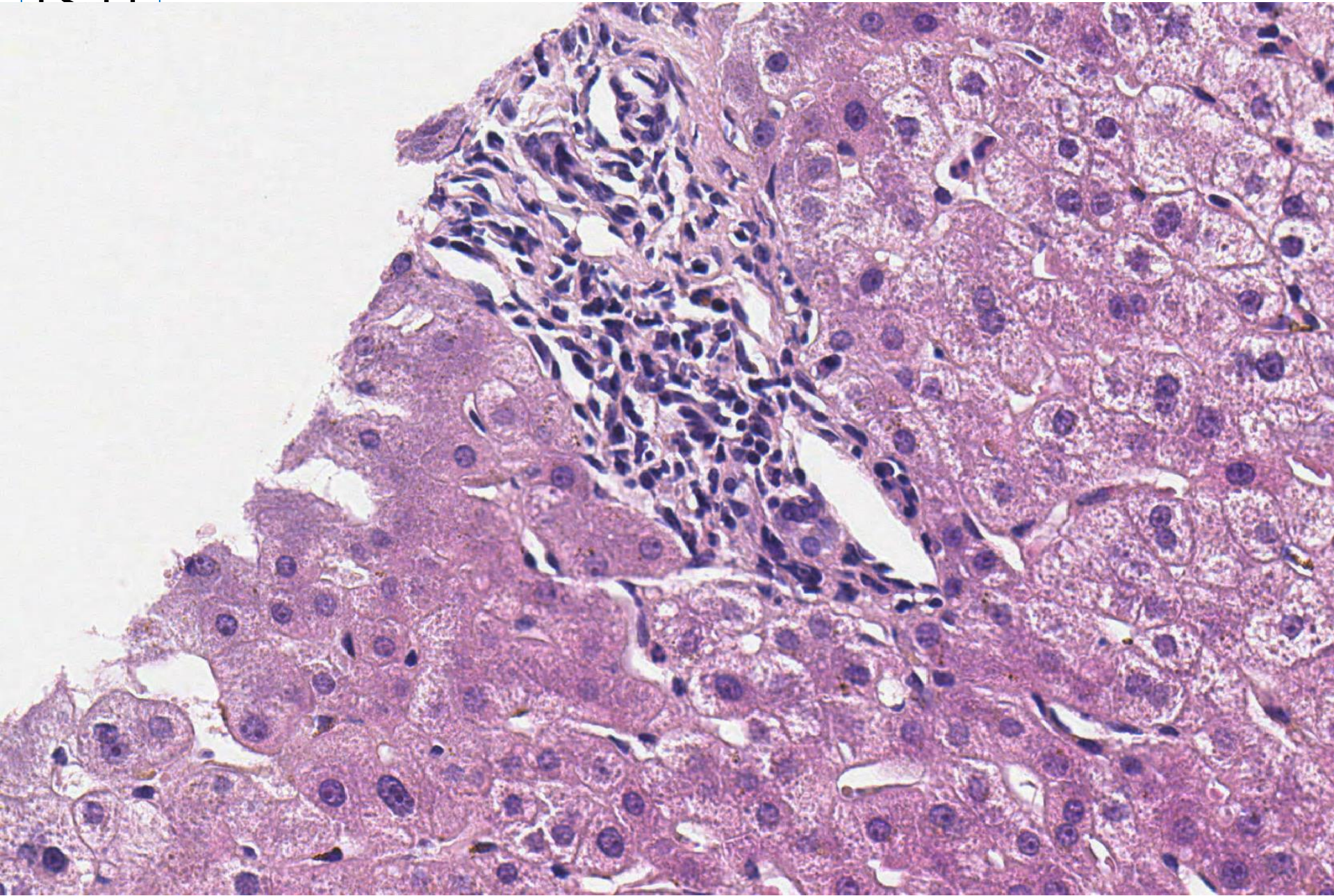
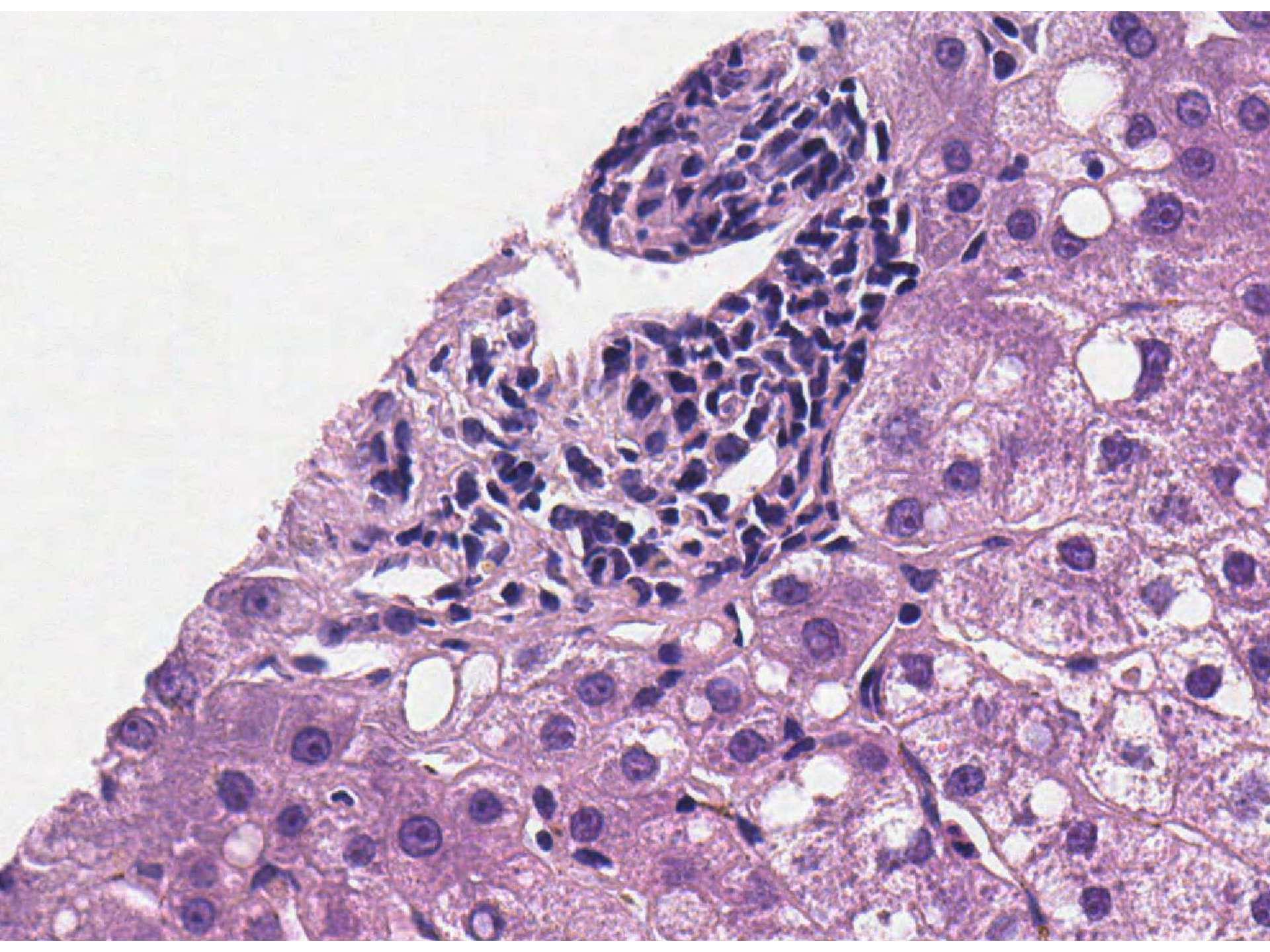


Case LS11 50 M

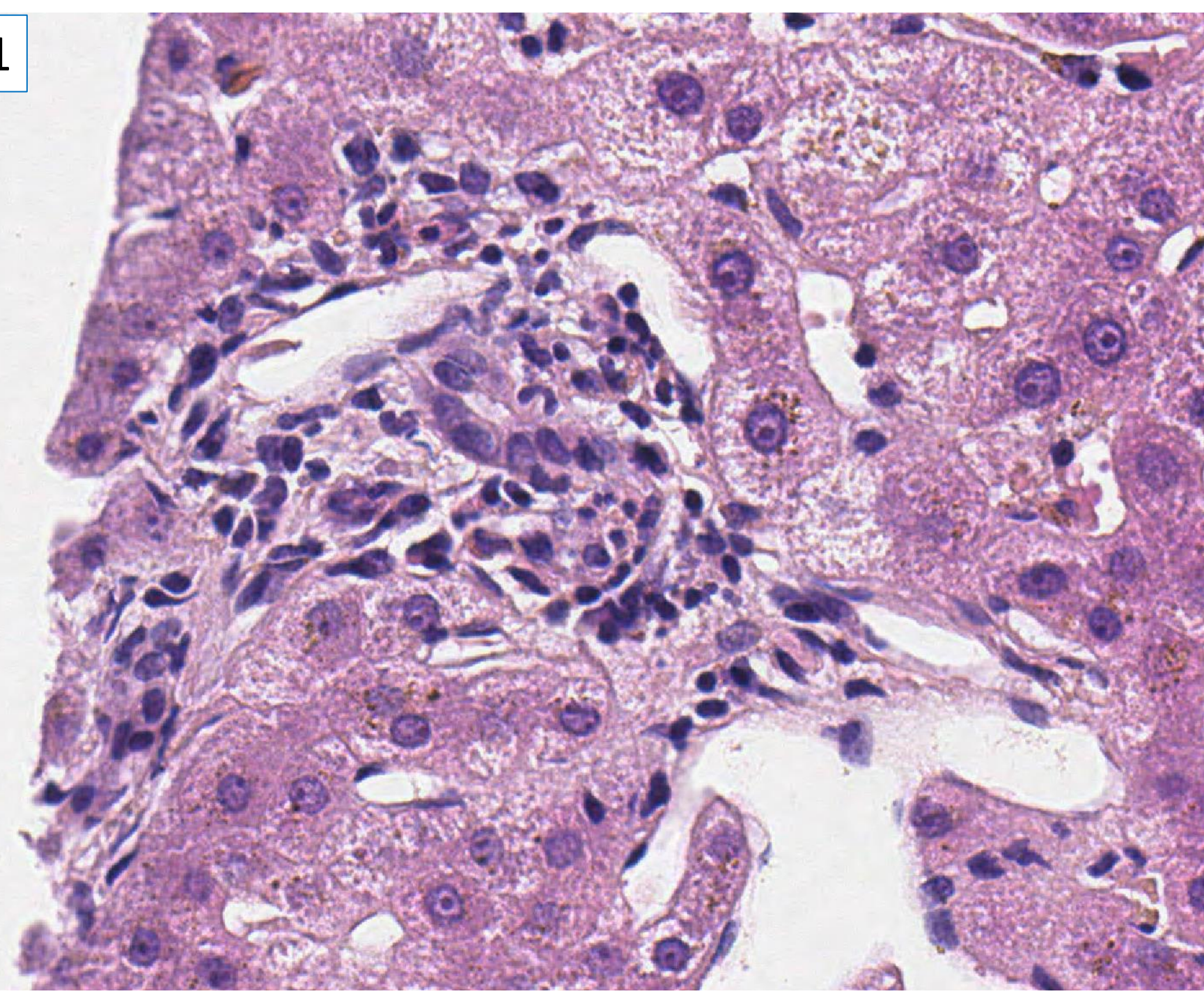
BMT for AML. Massively deranged LFTs, ALT 600
? GVHD, ? other liver pathology

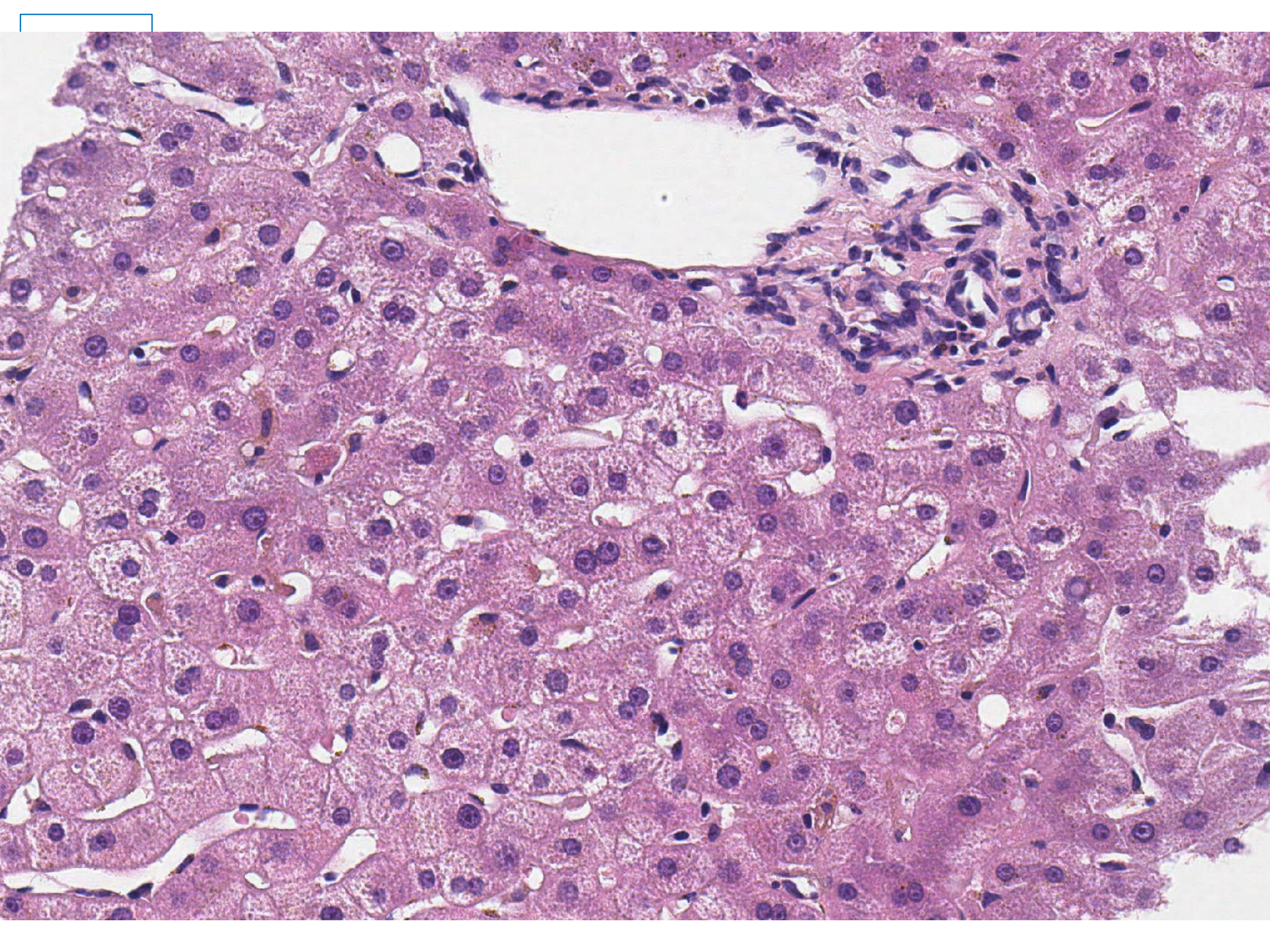




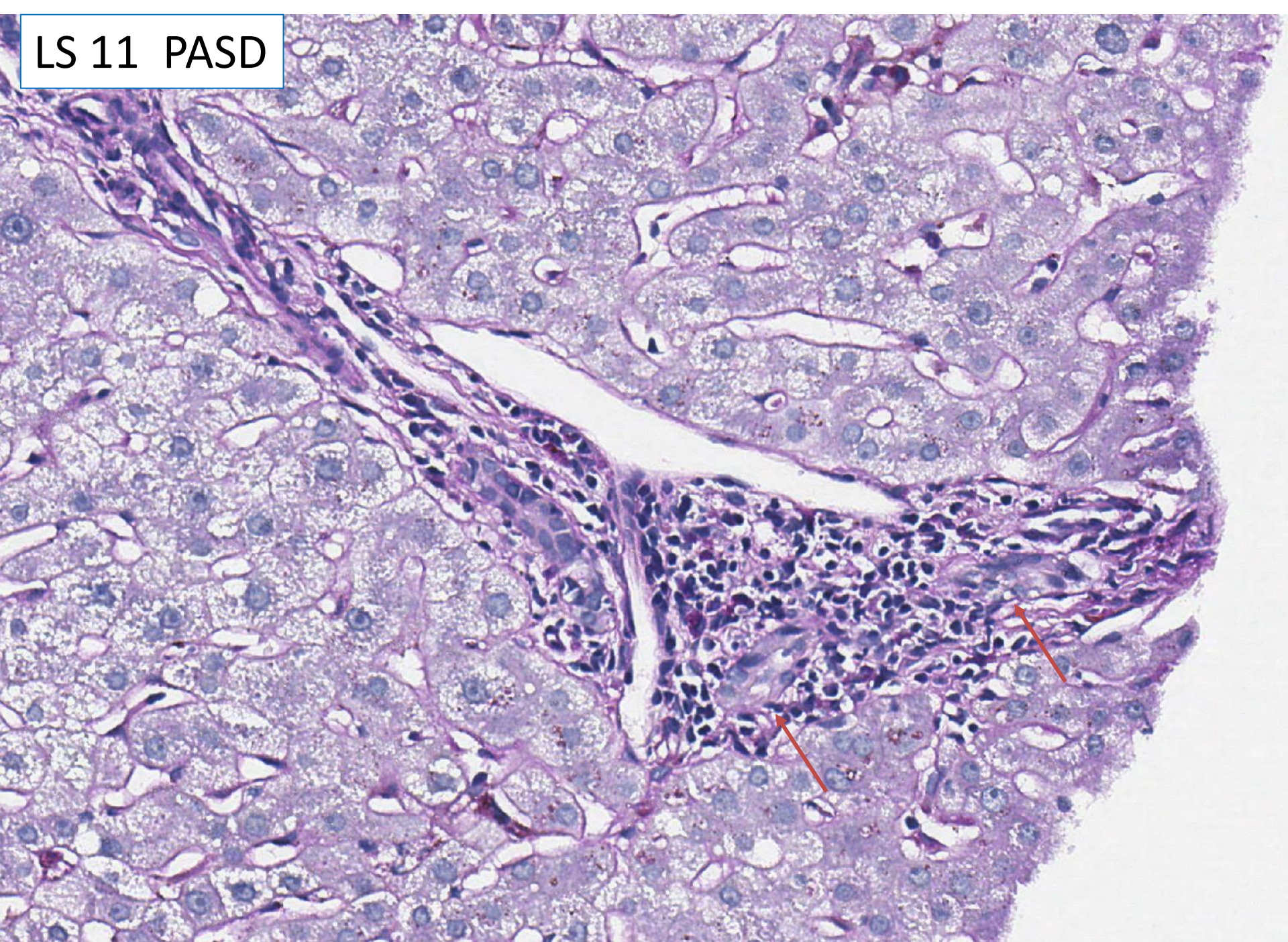


LS 11

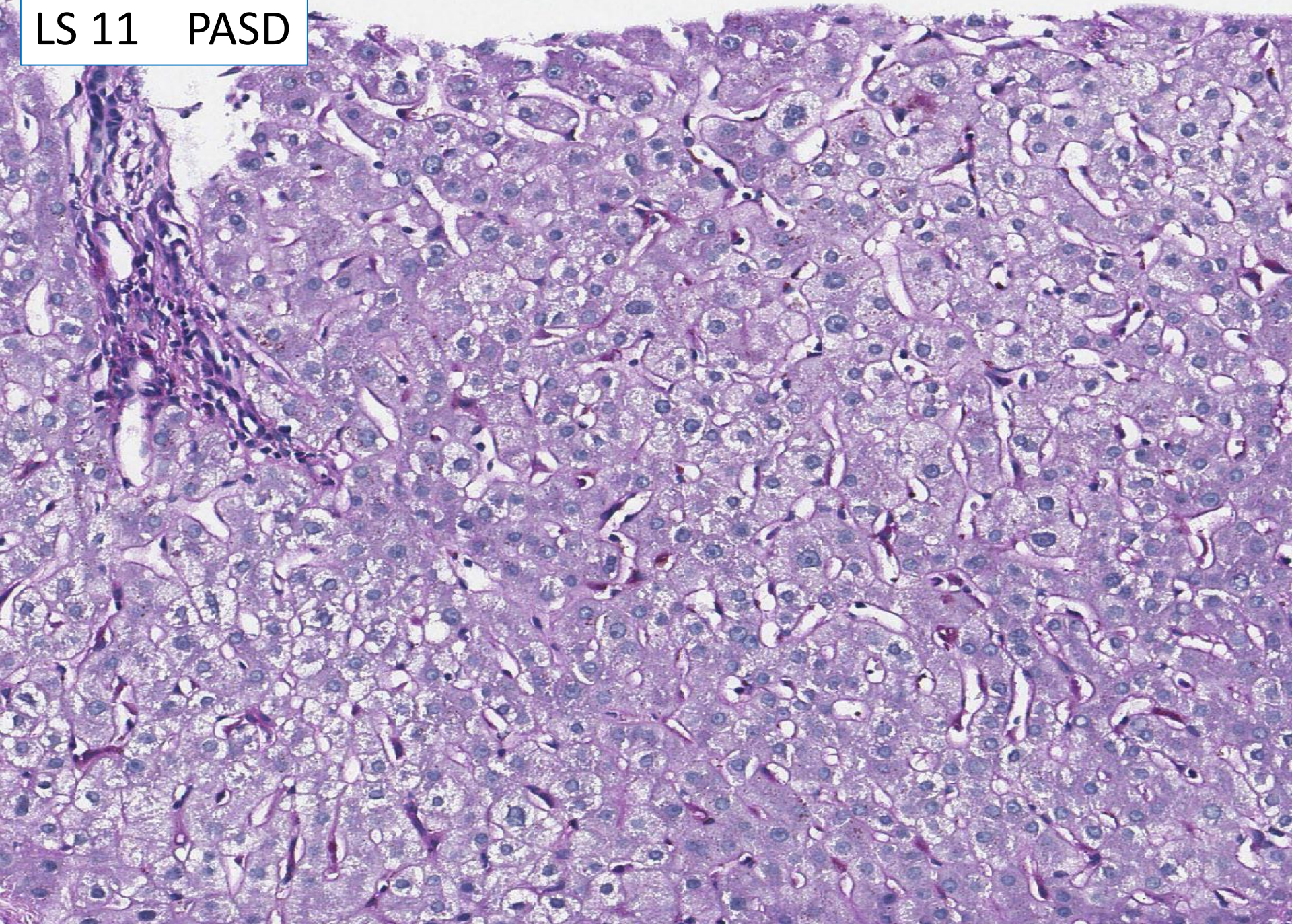




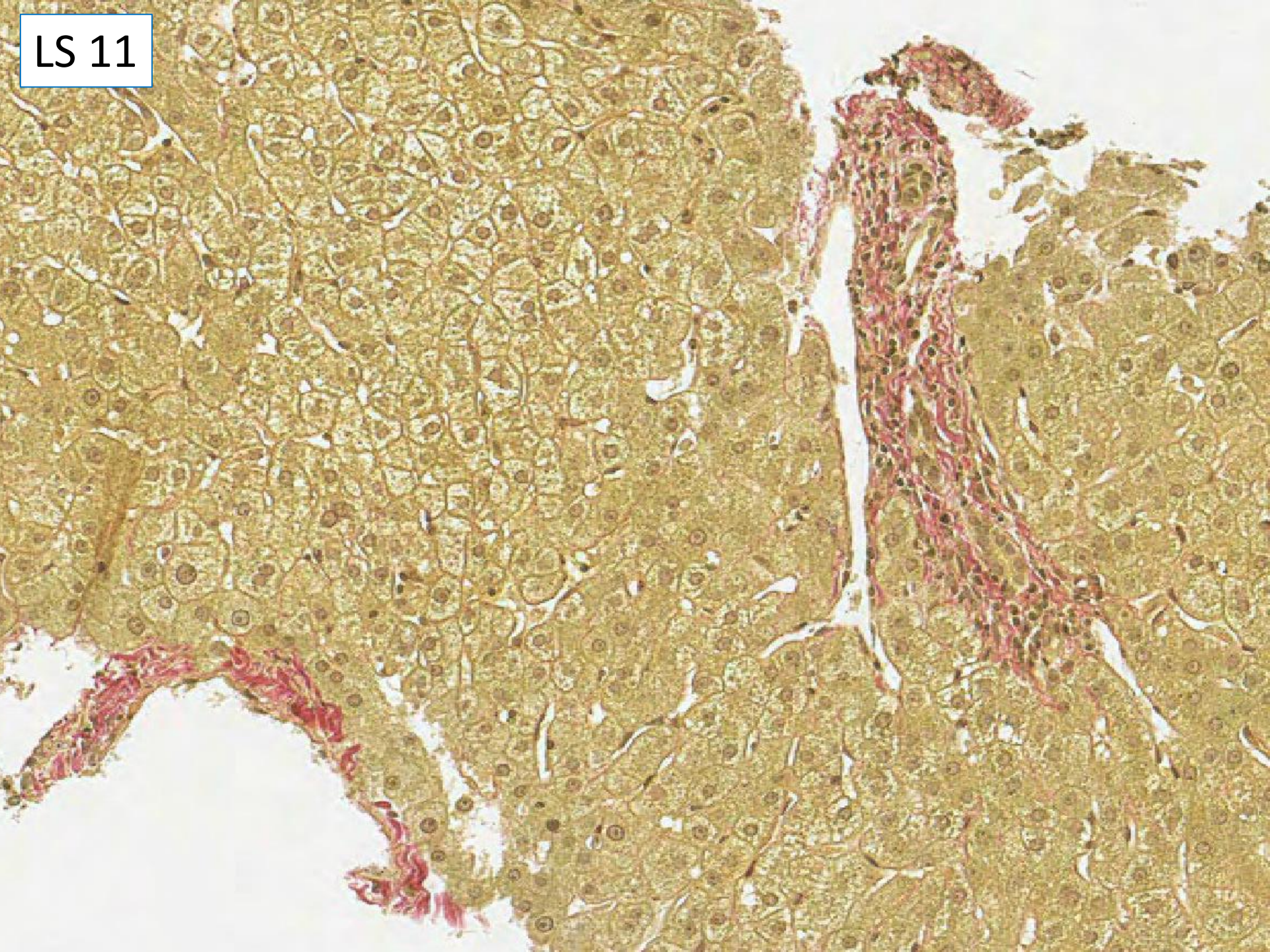
LS 11 PASD



LS 11 PASD



LS 11



Case LS11 50 M

MBT for AML 11.1.18. Massively deranged LFTs, ALT 600
? GVHD, ? other liver pathology

A	Resolving hepatitis ? EBV related
B	Suspicious of veno-occlusive disease
C	Consistent with graft v. host disease
D	Non-specific reactive changes
E	Infiltration by AML